

PATIENT PRESENTING CLINICAL SIGNS

Miss Spot Schmidt History: Bone tumor distal tibia – screening for metastatic disease prior to surgery.

SPECIES Physical Examination: Boney swelling distal tibia.

Canine Urinalysis: N/A.

BREED CBC: Lymphopenia.

Great Dane Serum Biochemistry: Top-normal creatinine, marginal hyperglycemia.

Radiographic Findings: N/A.

SEX

FS

ULTRASONOGRAPHIC EXAMINATION OF THE ABDOMEN

AGE *Urinary System*

7 years Full urinary bladder with a normal thickness and appearance of the wall. Normal anechoic urine with no sediment or uroliths evident.

WEIGHT Normal trigone area, proximal urethra, and iliac blood vessels.

120# Iliac lymph nodes and ureters not visualized.

INTERPRETED BY Normal renal size with increased echogenic appearance, some loss of cortico-medullary differentiation, capsule, and pelvis.

Remo Lobetti, BVSc,
MMedVet (Med), PhD,
Dipl. ECVIM

Reproductive System

N/A.

IMAGING PERFORMED BY

Adrenal Glands

Desen Ertunc Normal size, shape, and echogenic appearance. Left 2.65 cm, right 2.73 cm.

HOSPITAL NAME *Spleen*

Healing Spirit Animal Wellness Center Normal size and echogenic appearance. Smooth homogenous parenchyma, smooth curvi-linear capsule, normal vasculature and blood flow. No evidence of inflammatory, neoplastic, infarction, or infiltrative changes noted.

REFERRING VET *Liver*

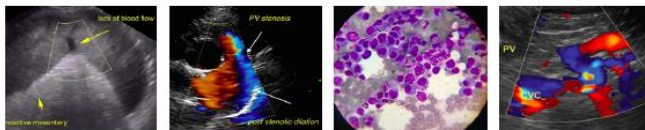
Desen Ertunc Normal size, echogenic appearance, and portal markings. No nodules or masses evident. Small gall bladder containing normal anechoic bile. Normal appearance and thickness of the gall bladder wall. Normal bile duct.

INVOICE *Gastrointestinal*

302603

DATE Normal appearance of the stomach, duodenum, small intestine, ileo-cecal junction, and colon with no loss of layering, normal wall thickness and peristaltic activity, and no lumen distension.

10/16/21



PATIENT *Pancreas*

Miss Spot Schmidt Normal size and echogenic appearance. Regular capsule. Normal echogenic appearance of the mesentery and fat surrounding the pancreas.

SPECIES *Free Abdomen*

Canine No mesenteric lymphadenopathy.

BREED No ascites.

Great Dane **ULTRASONOGRAPHIC FINDINGS**

SEX

FS

AGE

7 years

Primary findings:

- None.

Secondary findings:

- Age-related renal changes.

WEIGHT

120#

INTERPRETATION OF THE FINDINGS & FURTHER RECOMMENDATIONS

On this ultrasound there is no evidence of metastatic disease.

INTERPRETED BY

Remo Lobetti, BVSc,
MMedVet (Med), PhD,
Dipl. ECVIM

As bone tumors generally tend to metastasize to the lungs and other bony tissue, 3-view thoracic radiographs, full skeletal examination, and ideally whole-body CT should be done.

IMAGING PERFORMED BY

Desen Ertunc

HOSPITAL NAME

Healing Spirit Animal
Wellness Center

The information and recommendations provided are based on the images presented by the referring veterinarian. No evaluation can be communicated regarding pathology that was not visible in the image/video clips provided.

REFERRING VET

Desen Ertunc

Thank you for this referral. If the clinical or image interpretation does not parallel your findings or if I can be of any further assistance, please contact me.

Remo Lobetti, BVSc, MMedVet (Med), PhD, Dipl. ECVIM (Internal Medicine)
rlobetti@mweb.co.za

INVOICE

302603

DATE

10/16/21